

Clinical and Molecular Characterization of Thai Patients with Wiskott–Aldrich Syndrome

P. Amarinthukrowh*†‡², S. Ittiporn†‡², S. Tongkobpetch†‡, P. Chatchatee§, D. Sosothikul¶, V. Shotelersuk†‡ & K. Suphapeetiporn†‡

*Interdepartment Program of Biomedical Sciences, Faculty of Graduate School, Chulalongkorn University, Bangkok, Thailand; †Center of Excellence for Medical Genetics, Department of Pediatrics, Faculty of Medicine, Chulalongkorn University, Bangkok, Thailand; ‡Excellence Center for Medical Genetics, King Chulalongkorn Memorial Hospital, Thai Red Cross, Bangkok, Thailand; §Division of Allergy and Immunology, Department of Pediatrics, Faculty of Medicine, Chulalongkorn University, Bangkok, Thailand; and ¶Division of Pediatric Hematology/Oncology, Department of Pediatrics, Faculty of Medicine, Chulalongkorn University, Bangkok, Thailand

Received 13 August 2012; Accepted in revised form 26 September 2012

Correspondence to: D. Sosothikul, MD, Division of Pediatric Hematology/Oncology, Department of Pediatrics, Sor Kor Building 11th floor, King Chulalongkorn Memorial Hospital, Bangkok 10330, Thailand. E-mail: dsosothikul@hotmail.com

²These authors contributed equally to this work.

Introduction

Wiskott–Aldrich syndrome (WAS; MIM 301000) is an X-linked recessive primary immunodeficiency disorder caused by mutations in the gene encoding the WAS protein (WASP). *WASP* mutations result in a wide spectrum of clinical phenotypes. The most severe form, classic WAS, is characterized by thrombocytopenia with small-sized platelets, recurrent infections, eczema and increased susceptibility to autoimmune diseases and haematologic malignancies. The milder form, X-linked thrombocytopenia (XLT; MIM 313900), is usually limited to thrombocytopenia with absent or minor infections and eczema [1–4]. Patients with severe WAS mostly die from infection or bleeding within the first decades of life. Hematopoietic stem cell transplantation (HSCT) remains the only curative therapy for WAS [5, 6].

Abstract

Wiskott–Aldrich syndrome (WAS) is an X-linked recessive primary immunodeficiency disorder caused by mutations in the gene encoding the WAS protein (WASP). Classic WAS is characterized by thrombocytopenia with small-sized platelets, recurrent infections, eczema and increased susceptibility to autoimmune diseases and haematologic malignancies. Here, we reported on seven unrelated Thai individuals with classic WAS. In addition to clinical and immunologic characterization, mutation analysis by PCR-sequencing the entire coding region of *WASP* was performed. Recurrent and novel mutations were successfully identified. A nonsense mutation, the c.55C>T (p.Q19X), has not been previously described, expanding the mutational spectrum of *WASP*. The patient with this newly described mutation developed cow's milk allergy manifesting as angioedema and urticaria and had cytomegalovirus infection that was successfully treated with long-term ganciclovir. This study reported long-term follow-up of seven patients with molecular confirmation of WAS and infrequent features in the patient with classic WAS carrying the novel nonsense mutation.

The *WASP* gene contains 12 exons with coding regions of 1823 bp. Its gene product, WASP, contains 502 amino acids and has five major functional domains involved in intracellular signalling and actin cytoskeleton reorganization in response to cell stimulation. The WASP is predominantly expressed in hematopoietic cell lineages. Absent or defective WASP leads to dysfunctions in different leucocyte subgroups involved in innate, humoral and cellular immunity as well as impaired platelet formation [2, 7].

At least 300 different disease-causing mutations in *WASP* have been identified with the most common being missense mutations (Human Gene Mutation Database, <http://www.hgmd.cf.ac.uk>, accessed July, 2012) [8–10]. Six mutational hotspots are also described. Loss-of-function mutations in the *WASP* gene are responsible for WAS and XLT, whereas gain-of-function mutations in the region

encoding the conserved GTPase binding domain of WASP lead to X-linked congenital neutropenia [8, 11, 12].

Here, we described seven unrelated Thai patients with classic WAS including rare manifestations and identified a novel nonsense mutation.

Materials and methods

Patients

Seven unrelated patients from different families including one previously reported were included in this study [13]. Diagnosis of classic WAS was based on clinical manifestations of thrombocytopenia, recurrent infections and eczema. The patients' age of onset ranged from 6 days to 8 months. The patients aged from 4 months to 5 years at the time of diagnosis. Using previously published scoring criteria [14], patients were assigned scores to describe their clinical severity. All patients had scores of 4 or higher. Clinical details and laboratory findings are shown in Table 1. Of these seven patients, two received HSCT.

The study was approved by the institutional review board of the Faculty of Medicine of Chulalongkorn University, and written informed consent was obtained from each family in accordance with the Declaration of Helsinki.

WASP mutation analysis

Peripheral blood samples were collected from the probands and their available parents. Total RNA and genomic DNA were extracted from peripheral blood leucocytes using Qiagen RNA and DNA extraction kits (Qiagen, Valencia, CA, USA). Reverse transcription was performed using ImProm-IITM reverse transcriptase (Promega, Madison, WI, USA), according to the manufacturer's recommendations. WASP entire coding regions were PCR-amplified and sequenced as previously described [13]. The patient in which no mutation was detected in the coding region was screened for mutations in the WASP promoters [15] and evolutionarily conserved intronic regions predicted by the Alamut[®] software (Interactive Biosoftware, <http://www.interactive-biosoftware.com>). Primers and PCR conditions were shown in Table 2. Sequence data were analysed using Sequencher version 5.0 (Gene Codes Corporation, Ann Arbor, MI, USA). Mutations found in the patients were confirmed by direct sequencing of the genomic DNA using a set of primers and parameters according to their mutation sites. Identified mutations were confirmed by direct sequencing in the opposite direction. The available parents were also tested for the identified mutation by PCR-sequencing. The nucleotide position is in accordance with the WASP mRNA (Genbank Accession No. NM_000377).

Table 1 Clinical and molecular characteristics of Thai patients with classic WAS.

Case no.	Age of onset	Age at diagnosis	First manifestation	Other feature	Platelet count (/ul)	Platelet volume (fl)	HSCT	Score	Mutation	Mother as a carrier	Infection	Age at last follow-up
1	6 days	1 year	Bloody stool	AIHA	74,000	5.2	ND	5	c.1507T > A (p.X503R)	Positive	Pneumonia, chronic colitis, chronic OM, periorbital cellulitis	11 years and 8 months
2	4 months	1 year	Bloody stool	Absent	41,000	5.0	1 year and 4 months	4	No mutations in the coding, promoter and conserved intronic regions	N/A	Pneumonia, ARDS, CNS infection, diarrhoea	8 years
3	1 month	1 year	Bloody stool	Absent	29,000	8.0	ND	4	c.1272InsG (p.G424Gf&X494)	Positive	Pneumonia, salmonella-diarrhoea	3 years and 9 months
4	19 days	2 years	Bloody stool	Absent	7,400	5.3	2 years and 5 months	4	c.256C > T (p.R86C)	Negative	Pneumonia, infective diarrhoea	8 years and 11 months
5	5 months	5 years	Pneumonia and/ bloody stool	Absent	4,000	7.2	ND	4	IVS8+3 to 6 del GAGT	Positive	Pneumonia, chronic OM, salmonella diarrhoea	6 years
6	8 months	1 year and 5 months	Epistaxis/ petechiae	AIHA	13,000	4.1	ND	5	c.257G>A (p.R86H)	N/A	Chronic OM, recurrent skin abscess	4 years
7	7 days	4 months	Pneumonia	Absent	27,000	7.0	ND	4	c.55C > T (p.Q19X)	Negative	Pneumonia, septic shock, CMV infection, CNS infection	2 years and 6 months

HSCT, hematopoietic stem cell transplantation; AIHA, autoimmune haemolytic anaemia; OM, otitis media; ARDS, acute respiratory distress syndrome; CNS, central nervous system; CMV, cytomegalovirus; ND, not done; N/A, not available.

Table 2 Primers and PCR conditions for sequence analysis of the WASP promoter and conserved intronic regions.

Primer name	Primer sequences from 5' to 3'	Annealing temp (°C)	Product size (bp)
WASP AP-F	GGGACCCGACTTCAGTCATC	60	580
WASP AP-R	GAAGTCTCCTCCAGTCCCT		
WASP PP-F	GTCAAGTGGAGGAGGGTTCC	58	317
WASP PP-R	AAGAGTCGCTGGTTCTCGTG		
WASP intron 2F	GACTTGCAAGCCAGTTCTCA	60	978
WASP intron 2R	TTTCAGCTCAGCACCAGAGA		
WASP intron 7F	CCCAGTGGACCCACAGATTC	62	1183
WASP intron 7R	TTTGGAAAGGGTGGGTGGAAG		

AP, alternate promoter; PP, primary promoter.

Results

Clinical characteristics and immunologic features

All patients had clinical features consistent with the classic WAS, including thrombocytopenia with small-sized platelets, recurrent infections and eczema. The patients' age of onset ranged from 6 days to 8 months. Bleeding was the first manifestation in the majority of cases (85.7%, 6/7 cases) in which bloody stool was the most frequent presenting symptoms (71.4%, 5/7 cases). One patient was initially presented with pneumonia and hepatosplenomegaly. Cytomegalovirus (CMV) infection was subsequently confirmed. Of all the patients with recurrent infections, pneumonia was the most commonly found (85.7%, 6/7 cases). Other infections included central nervous system infections, infective diarrhoea caused by Salmonella, otitis media, sepsis and perianal abscess. The patients' clinical features are summarized in Table 1.

Immunoglobulin levels and lymphocyte subsets were evaluated in all patients (Table 3). Of these seven patients, higher IgE levels were detected in six (85.7%). Most however had normal IgG, IgA and IgM levels. A CD4/CD8 ratio < 1 was detected in three patients (42.9%). Two patients had a score of 5 as they developed autoimmune haemolytic anaemia (AIHA) at the age of 7 years (case 1) and 1 year and a half (case 6).

Regular intravenous immunoglobulin (IVIG) with a dose of 400 mg/kg/month was given to all patients. None underwent splenectomy. Two (cases 2 and 4) received HSCT at the age of 1 year and 4 months and 2 years and 5 months, respectively. The stem cell source was bone marrow from unrelated cord blood (case 2) or an HLA-matched sibling (case 4). Both had normal platelet counts within 2 months after HSCT and were alive. Of the patients without HSCT, one died at the age of 4 years due to intracerebral bleeding.

Cytomegalovirus infection was found in one patient (case 7) who presented with tachypnea at 2 months of age. He was the first child and born at term to nonconsanguineous parents after an uneventful pregnancy and delivery. His birth weight was 2970 g with head circumference of 30 cm (< 3rd centile). At the age of 2 months, his weight was 3220 g (< 3rd centile) with a length of 52 cm (< 3rd centile) and head circumference of 33 cm (< 3rd centile). He was moderately pale without petechiae. He had crepitation on both lungs and hepatosplenomegaly. Complete blood counts showed haemoglobin (Hb) 5.9 g/dl, white blood cells 15,790/μl (53% neutrophils, 37% lymphocytes, 7% monocytes and 3% eosinophils) and platelets 27,000/μl with a mean platelet volume of 7 fl. Chest x-rays revealed patchy infiltration of both lower lungs. Examination of the bone marrow aspirate revealed hypercellularity with increased megakaryocytes compatible

Table 3 Immunologic findings of Thai patients with classic WAS.

Patient	Immunoglobulin				Percent of lymphocytes					
	IgG (mg/dl) (700–1600)	IgA (mg/dl) (70–400)	IgM (mg/dl) (40–230)	IgE (IU/ml) (< 100)	CD3 (%) (46.2–82.7)	CD19 (%) (7.7–25.4)	CD4 (%) (24.1–50.7)	CD8 (%) (17.1–44.6)	CD56 (%) (3.9–38.5)	CD4/CD8 ratio
1	1641 (↑)	310.7	122	289.6 (↑)	84 (↑)	8	27	49	7	0.55
2	1513	99.8	195.6	359.9 (↑)	N/A	3 (↓)	10 (↓)	35	31	0.29
3	2428 (↑)	233.6	181.5	265.8 (↑)	40 (↓)	35	31	4 (↓)	21	7.75
4	1210	152	48.2	261.4 (↑)	54	27	42	10 (↓)	11	4.20
5	909.3	672.9 (↑)	49.9	397.2 (↑)	66	9.8	32.4	25.6	14.1	1.27
6	772	57.1 (↓)	96.3	75.3	73	13	46	23	11	2.00
7	1140	113	59.1	3750 (↑)	79	2 (↓)	11 (↓)	57	18	0.56

N/A, not available.

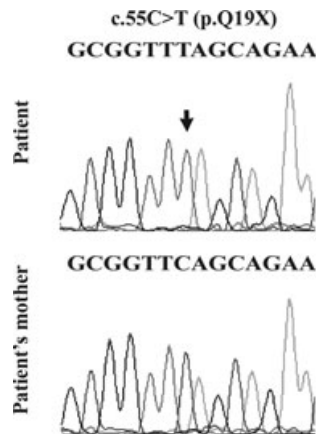


Figure 1 WASP mutation analysis. Upper panel: An electropherogram of patient 7 shows a hemizygous novel nonsense mutation c.55C>T (p.Q19X) (arrow). Lower panel: An electropherogram of the patient's mother shows normal genotypes.

with peripheral destruction of platelets. PCR test for CMV in peripheral blood revealed 5280 copies/ml. At 2 week follow-up, CMV viral load increased to 79,800 copies/ml. Treatment with ganciclovir (5 mg/kg every 12 h) was therefore initiated and continued for 7 weeks when viral load was reduced to 3120 copies/ml. After discontinuation of ganciclovir for 3 weeks, an increase in viral load to 57,600 copies/ml was noted. Ganciclovir was therefore resumed and continued for 6 months until viral load was below 1000 copies/ml. An ophthalmic exam, audiogram and brain ultrasonography showed normal findings at 3 months of age. Besides antiviral therapy, antimicrobials were given due to septicaemia and recurrent pneumonia. At the age of 4 months, erythematous rashes were found on his face and gradually spreading to the trunk and extremities. He also developed urticarial rashes and angioedema when cow milk was introduced. Immunologic studies revealed higher IgE levels and an inverted CD4/CD8 ratio (Table 2). Phytohemagglutinin stimulation test showed decreased T-cell proliferation. Mutation analysis of the WASP gene in the patient revealed a *de novo* nonsense mutation. At the age of 15 months, the patient had left

cerebellar haemorrhage with communicating hydrocephalus, which was gradually resolved. He was placed on monthly IVIG and sulfamethoxazole-trimethoprim prophylaxis. At the last visit when the patient was two and a half years old, he had speech delay but appropriate motor milestone.

Mutation analysis

PCR-sequencing revealed six different disease-causing mutations including one being novel in unrelated patients with clinical manifestations suspected of classic WAS (Table 1). Two cases harboured hot spot mutations (p.R86C/H). One patient was hemizygous for a nonsense mutation in exon 1, c.55C > T resulting in changing a glutamine at amino acid position 19 into a stop codon (p.Q19X) (Fig. 1). No other sequence alterations were found. The nonsense mutation (p.Q19X) presumably results in the formation of a truncated protein lacking most of the functional domains. This mutation has never been previously described. The patient's mother did not carry the mutation (Fig. 1).

No causative mutations could be identified in the coding and promoter regions of WASP in one patient (case 2). A previous study demonstrated disease-causing mutations in the evolutionarily conserved noncoding regions of the responsible gene [16]. This prompted us to evaluate evolutionary conservation of nucleotide sequences using the Alamut[®] software (Interactive Biosoftware, <http://www.interactive-biosoftware.com>) (Fig. 2). In addition to the highly conserved exonic regions, two intronic regions (introns 2 and 7) of the WASP were found to have apparent high evolutionary conservation. PCR-sequencing, however, did not detect any variants.

Discussion

We previously described the termination codon mutation in the WASP gene in a Thai family affected with classic WAS [13]. This study further reported the clinical manifestations and long-term follow-up of seven unrelated patients with molecular diagnosis of classic WAS. In

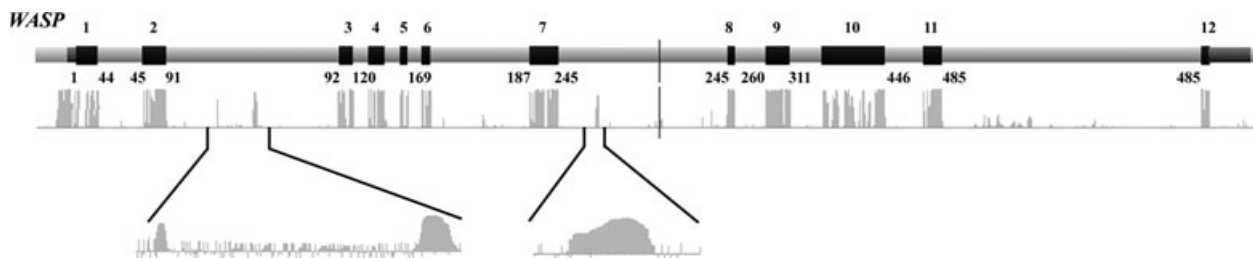


Figure 2 Evolutionary conservation of nucleotide sequences using the Alamut[®] software. In addition to the highly conserved exonic regions (black boxes) of the WASP gene, two intronic regions (introns 2 and 7) (grey line) were found to have high evolutionary conservation. Grey bars indicate evolutionary nucleotide conservation.

addition to the previously reported mutation, four different recurrent mutations were identified, including two missense mutations, an insertion and a 4-bp deletion in intron 8. One novel nonsense (c.55C > T, p.Q19X) mutation was also detected.

No causative mutations in the coding, promoter and conserved intronic regions could be identified in case 2. The patient had classic WAS with a score of 4, and no WASP expression could be detected in his cells by immunoblot analysis (courtesy of Dr. Hubert B. Gaspar and Dr. Kimberly C. Gilmour, UK). It remains possible that the mutation could be located in the noncoding parts of the gene including regulatory regions.

Our patients with classic WAS had the age of onset ranging from 6 days to 8 months. Of these seven cases, two developed AIHA, which included the previously reported patient (case 1) with the c.1507T > A (p.X503R) mutation (Table 1). As there are no available HLA-matched donors, this patient has been given monthly IVIG and sulfamethoxazole-trimethoprim prophylaxis. The missense mutations (p.R86N) at position 86, one of the common hot spot mutations found in the WASP gene, were identified in two unrelated patients. One with a WAS score of 4 carried the c.256C > T (p.R86C) mutation. The other with a WAS score of 5 harboured the c.257G > A (p.R86H) mutation. The missense mutations at position 86 (p.R86N) have been found to be commonly associated with the XLT phenotype. However, some patients with these particular mutations can have a more severe phenotype with a score of 3–5 [10, 12, 17]. The previously reported c.1272insG (p.G424GfsX494) and IVS8 + 3 to 6del GAGT mutations in patients with classic WAS were also detected in the Thai population.

The novel nonsense (c.55C > T, p.Q19X) mutation expected to result in the formation of a truncated protein lacking most of the functional domains was identified in one patient with severe WAS. He developed pneumonia with hepatosplenomegaly at 2 months of age caused by CMV. As microcephaly was observed at birth, congenital CMV infection cannot be excluded. Previous studies described CMV infection in patients with WAS both prior to and following HSCT [10, 18–20], and it resulted in a fatal outcome in the majority of cases. The treatment guideline for CMV infection in patients with WAS, however, has not been well established. A small number of WAS patients with CMV infection have been successfully treated with 1-month ganciclovir followed by 1-month famciclovir [21] or HSCT [20, 22]. Our patient was successfully treated with 6 months of ganciclovir therapy. Our studies supported the early and prolonged ganciclovir therapy in WAS patients with CMV infection for a better outcome.

This patient also developed urticaria and angioedema caused by ingestion of cow milk. His IgE levels were 3750 IU/ml. This feature was rarely described in WAS. Whether cow's milk allergy (CMA) is associated with

WAS remains unclear. As most of the patients with WAS have markedly elevated serum IgE levels, and CMA can be IgE-mediated, IgE could be an important contributory factor in the pathogenesis of CMA in WAS. Further studies of CMA in WAS patients could lead to new insights into the immune pathomechanism of CMA.

In summary, we reported the clinical manifestations and long-term follow-up of seven unrelated Thai patients with molecular confirmation of WAS. Six different mutations including one nonsense mutation were identified, expanding the mutational spectrum of WASP. The patient with this novel mutation had CMV infection, which was successfully treated with long-term ganciclovir. He also developed angioedema and urticaria as a result of cow's milk allergy.

Acknowledgment

This study was supported by the Royal Golden Jubilee Ph. D. Program to PA (Grant No. PHD/0202/2552), the National Science and Technology Development Agency, the Thailand Research Fund, and the National Research University Project, office of the Higher Education Commission (HR1163A).

References

- 1 Aldrich RA, Steinberg AG, Campbell DC. Pedigree demonstrating a sex-linked recessive condition characterized by draining ears, eczematoid dermatitis and bloody diarrhea. *Pediatrics* 1954;13:133–9.
- 2 Derry JM, Ochs HD, Francke U. Isolation of a novel gene mutated in Wiskott-Aldrich syndrome. *Cell* 1994;79:following 922.
- 3 Ochs HD, Thrasher AJ. The Wiskott-Aldrich syndrome. *J Allergy Clin Immunol* 2006;117:725–38. quiz 39.
- 4 Villa A, Notarangelo L, Macchi P *et al.* X-linked thrombocytopenia and Wiskott-Aldrich syndrome are allelic diseases with mutations in the WASP gene. *Nat Genet* 1995;9:414–17.
- 5 Imai K, Morio T, Zhu Y *et al.* Clinical course of patients with WASP gene mutations. *Blood* 2004;103:456–64.
- 6 Ozsahin H, Cavazzana-Calvo M, Notarangelo LD *et al.* Long-term outcome following hematopoietic stem-cell transplantation in Wiskott-Aldrich syndrome: collaborative study of the European Society for Immunodeficiencies and European Group for Blood and Marrow Transplantation. *Blood* 2008;111:439–45.
- 7 Ochs HD, Notarangelo LD. Structure and function of the Wiskott-Aldrich syndrome protein. *Curr Opin Hematol* 2005;12:284–91.
- 8 Jin Y, Mazza C, Christie JR *et al.* Mutations of the Wiskott-Aldrich Syndrome Protein (WASP): hotspots, effect on transcription, and translation and phenotype/genotype correlation. *Blood* 2004;104:4010–19.
- 9 Ochs HD. Mutations of the Wiskott-Aldrich Syndrome Protein affect protein expression and dictate the clinical phenotypes. *Immunol Res* 2009;44:84–8.
- 10 Zhang ZY, Xiao HQ, Jiang LP *et al.* Analysis of clinical and molecular characteristics of Wiskott-Aldrich syndrome in 24 patients from 23 unrelated Chinese families. *Pediatr Allergy Immunol* 2010; 21:522–32.
- 11 Derry JM, Kerns JA, Weinberg KI *et al.* WASP gene mutations in Wiskott-Aldrich syndrome and X-linked thrombocytopenia. *Hum Mol Genet* 1995;4:1127–35.

- 12 Kolluri R, Shehabeldin A, Peacocke M *et al.* Identification of WASP mutations in patients with Wiskott-Aldrich syndrome and isolated thrombocytopenia reveals allelic heterogeneity at the WAS locus. *Hum Mol Genet* 1995;4:1119–26.
- 13 Chatchatee P, Srichomthong C, Chewatavorn A, Shotelersuk V. A novel termination codon mutation of the WAS gene in a Thai family with Wiskott-Aldrich syndrome. *Int J Mol Med* 2003;12:939–41.
- 14 Ochs HD. The Wiskott-Aldrich syndrome. *Isr Med Assoc J* 2002;4:379–84.
- 15 Hagemann TL, Kwan SP. The identification and characterization of two promoters and the complete genomic sequence for the Wiskott-Aldrich syndrome gene. *Biochem Biophys Res Commun* 1999;256:104–9.
- 16 Meeths M, Chiang SC, Wood SM *et al.* Familial hemophagocytic lymphohistiocytosis type 3 (FHL3) caused by deep intronic mutation and inversion in UNC13D. *Blood* 2011;118:5783–93.
- 17 Albert MH, Bittner TC, Nonoyama S *et al.* X-linked thrombocytopenia (XLT) due to WAS mutations: clinical characteristics, long-term outcome, and treatment options. *Blood* 2010;115:3231–8.
- 18 Richter D, Hampl W, Pohlandt F. Vertical transmission of cytomegalovirus, most probably by breast milk, to an infant with Wiskott-Aldrich syndrome with fatal outcome. *Eur J Pediatr* 1997;156:854–5.
- 19 Lee PP, Chen TX, Jiang LP *et al.* Clinical and molecular characteristics of 35 Chinese children with Wiskott-Aldrich syndrome. *J Clin Immunol* 2009;29:490–500.
- 20 Almagor Y, Revel-Vilk S, Averbuch D *et al.* Congenital cytomegalovirus infection and Wiskott-Aldrich syndrome successfully treated with unrelated cord blood transplantation. *Pediatr Blood Cancer* 2011;57:681–3.
- 21 Lee WI, Huang JL, Jaing TH, Wu KH, Chien YH, Chang KW. Clinical aspects and genetic analysis of taiwanese patients with wiskott-Aldrich syndrome protein mutation: the first identification of x-linked thrombocytopenia in the chinese with novel mutations. *J Clin Immunol* 2010;30:593–601.
- 22 Kaneko M, Watanabe T, Watanabe H *et al.* Successful unrelated cord blood transplantation in an infant with Wiskott-Aldrich syndrome following recurrent cytomegalovirus disease. *Int J Hematol* 2003;78:457–60.